

Effects of Testosterone Treatment on Endometrial Proliferation in Postmenopausal Women

Hong Zang, Lena Sahlin, Britt Masironi, Elina Eriksson, and Angelica Lindén Hirschberg

Department of Woman and Child Health, Divisions of Obstetrics and Gynecology (H.Z., A.L.H.) and Reproductive Endocrinology (L.S., B.M.), and Department of Oncology–Pathology (E.E.), Division of Pathology, Karolinska Institutet, SE-171 76, Stockholm, Sweden

Context: Available data concerning effects of testosterone on endometrium of postmenopausal women are seriously limited.

Objective: Our aim was to compare the influence of treatment with testosterone and/or estrogen on endometrial proliferation in healthy postmenopausal women.

Design: This was an open, randomized clinical study with parallel comparison of the groups.

Setting: The study was conducted at a women's health clinical research unit and a research laboratory at a university hospital.

Participants: Sixty-three women who had experienced natural menopause participated in this study.

Interventions: After random assignment, the participants were administered orally testosterone undecanoate (40 mg every second day), estradiol valerate (2 mg daily), or both for 3 months.

Main Outcome Measures: Endometrial thickness was measured,

and endometrial proliferation evaluated on the basis of histopathology and expression of Ki-67, a proliferation marker.

Results: Endometrial thickness was significantly increased by treatment with estrogen alone or in combination with testosterone but was unaltered by testosterone alone. Among the women receiving estrogen alone, the proportion exhibiting histopathology indicative of proliferation increased significantly to 50% ($P < 0.05$), there was a non-significant increase to 28% with the combined treatment, whereas testosterone alone had no effect at all. Expression of Ki-67 was up-regulated significantly in both glands and stroma ($P < 0.05$, respectively) in both estrogen treatment groups. However, the expression was significantly higher in stroma by estrogen treatment alone than after combined treatment ($P < 0.05$).

Conclusions: The short-term treatment with testosterone of postmenopausal women does not stimulate endometrial proliferation. In addition, testosterone appears to counteract endometrial proliferation induced by estrogen to a certain extent. (*J Clin Endocrinol Metab* 92: 2169–2175, 2007)

IT IS WELL KNOWN that estrogen stimulates proliferation of the endometrium, a target for sex hormones, and that long-term treatment of postmenopausal women with estrogen alone promotes endometrial hyperplasia and increases the risk of endometrial cancer (1). In contrast, progesterone exerts antiproliferative effects on this tissue and is therefore used to supplement estrogen treatment to prevent endometrial proliferation (2). Sex hormones act via specific receptors, and, in addition to estrogen and progesterone receptors, the androgen receptor is expressed by stromal and epithelial cells of the human endometrium (3).

In recent years, the interest in treating postmenopausal women with androgens has been increasing because of the beneficial effects of such treatment on libido, bone mass, and general well-being (4–7). However, at present, our knowledge concerning possible side effects and the safety of this approach, as well as the basic biological effects of androgens on the endometrium, is severely limited. Indeed, the few published re-

ports in this area contain discrepant findings. Testosterone inhibits the growth of human endometrial cells *in vitro* (8). Narukawa *et al.* (9) demonstrated that androgens induce prolactin production in the human endometrium, an effect that is associated with stromal cell differentiation. However, in postmenopausal women receiving testosterone and estrogen in combination, endometrial hyperplasia similar to that observed with estrogen alone has been detected (10, 11). To date, we have no knowledge concerning the effects of testosterone alone on the endometrium of postmenopausal women.

In the present open but randomized study, we examined the effects of treating healthy postmenopausal women with testosterone and/or estrogen on endometrial proliferation. Before and after 3 months of such treatment, the thickness of the endometrium was determined by transvaginal ultrasonography, and endometrial proliferation was evaluated by histopathology and examination of the expression of Ki-67, a marker for proliferation.

Subjects and Methods

Subjects

Postmenopausal women 44 to 64 yr of age and with a body mass index (BMI) between 20 and 32 kg/m² participated in the study. All subjects had experienced their last menstrual bleeding at least 12 months before beginning the study or exhibited serum levels of FSH greater than 30 IU/liter. The women receiving hormone therapy (HT) were required to discontinue treatment for 8 wk in the case of oral therapy and 4 wk for transdermal or local application of estrogen before initiation of our investigation. The criteria used for exclusion were as follows: the pres-

First Published Online March 6, 2007

Abbreviations: BMI, Body mass index; E group, group that received oral administration of E₂V; E₂V, estradiol valerate; ER, estrogen receptor; HT, hormone therapy; T group, group that received oral treatment with TU; T+E group, group that received oral treatment with both E₂V and TU; TU, testosterone undecanoate.

JCEM is published monthly by The Endocrine Society (<http://www.endo-society.org>), the foremost professional society serving the endocrine community.

ence of liver, biliary, or renal disease; uncontrolled high blood pressure; endocrinological disorder; a history or presence of thromboembolic disorder; and malignancy. In addition, only nonsmokers were included. The study was approved by the Ethics Committee of Karolinska University Hospital, and the subjects all gave their informed consent before participation.

Study design

The women were randomly assigned into three groups (1:1:1) by a research nurse according to the code generated from the permuted block randomization (blocks of $3 \times 4 = 12$ subjects). One group (T group) received oral treatment with testosterone undecanoate (TU) (40 mg every other day; Organon, Oss, The Netherlands), the second group (E group) received oral administration of estradiol valerate (E₂V) (2 mg daily; Orion Pharma, Esbo, Finland), and the third group (T+E group) received both testosterone and estradiol (in these same forms, doses, and schedules) for a total of 3 months. The women were instructed to take TU with their evening meal. All of the women were examined both immediately before and at the end of the treatment period as follows: after an overnight fast, a general health examination, including registration of body weight, height, and blood pressure, was performed at the Women's Health Research Unit at the Karolinska University Hospital. A fasting blood sample was drawn from a peripheral vein 12 or 36 h after intake of TU, and serum was separated by centrifugation and then stored at -70°C for later analysis of sex hormones.

In addition, gynecological examination, including measurement of endometrial thickness by transvaginal ultrasonography using a 7.5 MHz vaginal probe (Siemens, Sonoline, Germany), was performed by the same investigator in all cases. Under local anesthesia, samples of endometrial tissue were obtained by both aspiration biopsy (Endorette; Medscand Medical, Malmö, Sweden) for histopathological examination at the Department of Pathology and uterine curettage for immunohistochemical analyses at our research laboratory. All tissue samples were fixed in 4% formaldehyde and embedded in paraffin for these purposes.

Endometrial histopathology

Endometrial histopathology was evaluated by a pathologist who did not know from which groups the samples originated or the order of sampling. In the context, the following histological classifications were used: 1) insufficient tissue: no/insufficient tissue for evaluation; 2) atrophic endometrium: only small glands with a single layer of inactive cuboidal epithelium; 3) inactive endometrium: glands with stratified, columnar epithelium without any mitoses; 4) proliferative endometrium: glands lined by stratified columnar cells with mitoses; 5) proliferative endometrium demonstrating glandular hyperplasia without atypia: proliferation of endometrial glands and an increased gland-to-stroma ratio (12, 13).

Immunohistochemical analysis

The nuclear antigen Ki-67 is expressed only by proliferating cells, in the G₁, S, and G₂ phases of the cell cycle and during mitosis (14). Immunostaining for this antigen using the avidin–biotin peroxidase complex procedure (15) was therefore used to identify proliferating endometrial cells. The 5 μm paraffin sections prepared from endometrial tissue were first dewaxed in Bioclear (Bio-Optica, Milan, Italy), rehydrated, and washed (pH 7.4) with PBS. Thereafter, these sections were subjected to microwave antigen retrieval in 0.01 M sodium citrate buffer (pH 6.0) for 10 min and then allowed to cool for 20 min. Subsequently, endogenous peroxidase activity was quenched by immersion in 3% hydrogen peroxide (Merck, Darmstadt, Germany) in methanol for 10 min at room temperature, after which nonspecific binding of the primary antibody was blocked by incubation with 1.5% normal horse serum (Vector Laboratories, Burlingame, CA) in PBS for 30 min at room temperature.

The sections were then incubated overnight at 4°C with mouse monoclonal antibody against Ki-67 (diluted 1:200 with PBS; catalog no. NCL-Ki-67-MM1; Novocastra, Newcastle, UK) or, in the case of the negative control, with a mouse IgG at a corresponding concentration. The next incubations were with a biotinylated horse antimouse secondary antibody (catalog no. BA-2000; Vector Laboratories) and 1.5% normal horse

serum in PBS, followed by an avidin–biotin peroxidase complex (Vectastain Elite, catalog no. PK-6100; Vector Laboratories), each time for 30 min at room temperature. Finally, the peroxidase substrate 3,3'-diaminobenzidine (catalog no. K3466; DakoCytomation, Carpinteria, CA) was added to obtain the colored reaction product.

Image analysis

A Leica (Nussloch, Germany) microscope connected to a computer using Colorvision software (Leica) was used to assess Ki-67 immunostaining quantitatively by a computer imaging analysis system (16). Quantification of immunostaining was performed on the digitized images of systematic randomly selected fields of endometrium, of which stroma, and glandular epithelium were analyzed separately. Ten fields were analyzed and measured separately in each slide of stroma and glands. For the slides with less than 10 fields, all fields were adopted. Luminal epithelium was not present in a sufficient amount to be analyzed. With use of color-discrimination software, the total area of positively stained cell nuclei (brown reaction product) was measured and expressed as a ratio of the total area of cell nuclei (brown reaction product plus blue hematoxylin).

Serum hormone levels

Serum levels of FSH, sex hormones, and SHBG were analyzed as described previously (17).

Statistical analysis

The values obtained are expressed as means \pm sds or medians and quartile ranges (25th to 75th quartiles, based on distribution). The paired *t* test or Wilcoxon's matched pairs test was used to compare differences within groups on the basis of the distribution of values. The Kruskal–Wallis test, followed by the Student's *t* test or the Mann–Whitney *U* test was used to evaluate differences between groups.

For analysis of the histopathological data, samples categorized as demonstrating an insufficient amount of tissue, atrophic endometrium, or inactive endometrium were combined and designated as representing an atrophic pattern, whereas samples exhibiting proliferative endometrium and endometrium with hyperplasia were considered together to represent a proliferative pattern. For subsequent comparison of endometrial histopathology, the sign test was used to evaluate possible differences within groups, and the χ^2 or Fisher's exact test was used for differences between groups.

Possible correlations between variables were evaluated using the Spearman's rank order correlation test. In all cases, a *P* value of <0.05 was considered to be statistically significant.

Results

Of the 75 women assessed for eligibility, nine did not fulfill the criteria for inclusion. Of the 66 women randomly assigned to the different experimental groups, two in the T group and one in the T+E group discontinued the experimental treatment for reasons not related to this treatment itself (Fig. 1).

The clinical characteristics of the 63 postmenopausal women in our three different groups immediately before and after 3 months of treatment are documented in Table 1. Before initiation of treatment, these subjects were similar with regard to present age, age at the time of menopause, BMI, the number who had previously received HT, serum levels of hormones, and endometrial thickness. There was no significant difference in FSH levels between women who had previously taken HT and those who had not (data not shown).

Circulating levels of total and free testosterone were, as expected, increased by treatment with TU. The median levels of total testosterone after such treatment were within the normal range for premenopausal women (9–87 ng/dl) as

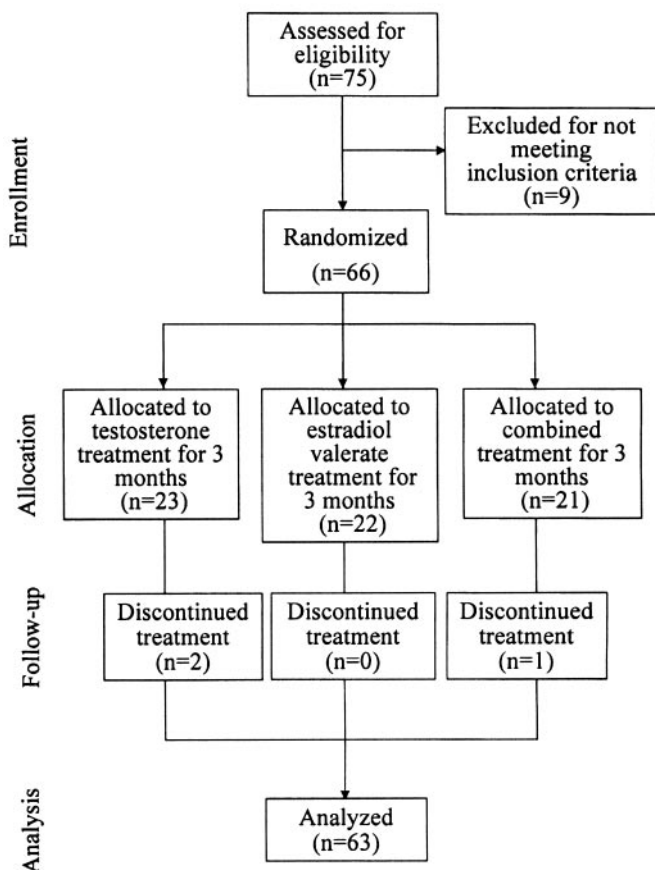


FIG. 1. A schematic diagram illustrating the present study.

determined by our procedure. As also expected, serum levels of estradiol and SHBG were significantly elevated in both groups that received E₂V. Serum levels of FSH were decreased by E₂V but were unaltered by TU alone (Table 1).

There were slight but significant increases in the mean BMI for all three groups by the end of the treatment period. Endometrial thickness remained unchanged in the T group but was enhanced significantly by more than 3-fold in both groups receiving estradiol ($P < 0.001$ in both cases) (Table 1).

Endometrial histopathology

An amount of endometrial tissue sufficient for histopathological evaluation of the same subject both before and after treatment was obtained from 15 women in the T group and 18 women each in the E and T+E groups. The histopathology of these tissue samples is presented in Fig. 2. Immediately before treatment, all subjects in all three of the groups exhibited an atrophic or inactive endometrium, with the exception of one woman in the E group, whose endometrium was proliferative. After 3 months of treatment, the endometrial histopathology of the T group was unaltered. In the E group, seven subjects had a proliferative endometrium and two simple hyperplasia, whereas in the T+E group, there were only four cases of proliferative endometrium and one of simple hyperplasia.

The relative proportions of atrophic and proliferative endometrium (atrophic and proliferative pattern) in the three groups before and after treatment are shown in Table 2. All of the women in the T group demonstrated an atrophic pattern (*i.e.* exhibiting histopathology of insufficient tissue/atrophic or inactive endometrium) both before and after treatment. In the case of the E group, the proportion of women with proliferative pattern (*i.e.* exhibiting histopathology of proliferative/hyperplastic endometrium) was increased significantly from 6 to 50% ($P < 0.05$) with a hyperplasia rate of 11% as a consequence of the treatment, whereas the corresponding increase from 0 to 28% in the T+E group was not statistically significant. After treatment, the proportions of proliferative pattern in the E and T+E groups were significantly higher than in the T group ($P < 0.001$ and $P < 0.05$, respectively). Furthermore, the proportion of women in the E group that exhibited proliferative endometrial histopathology after treatment tended to be greater than in the T+E group ($P = 0.09$). In addition, analysis of the findings for all subjects revealed a positive correlation between the change in endometrial thickness and endometrial histopathology ($r = 0.4$; $P < 0.01$).

Expression of Ki-67

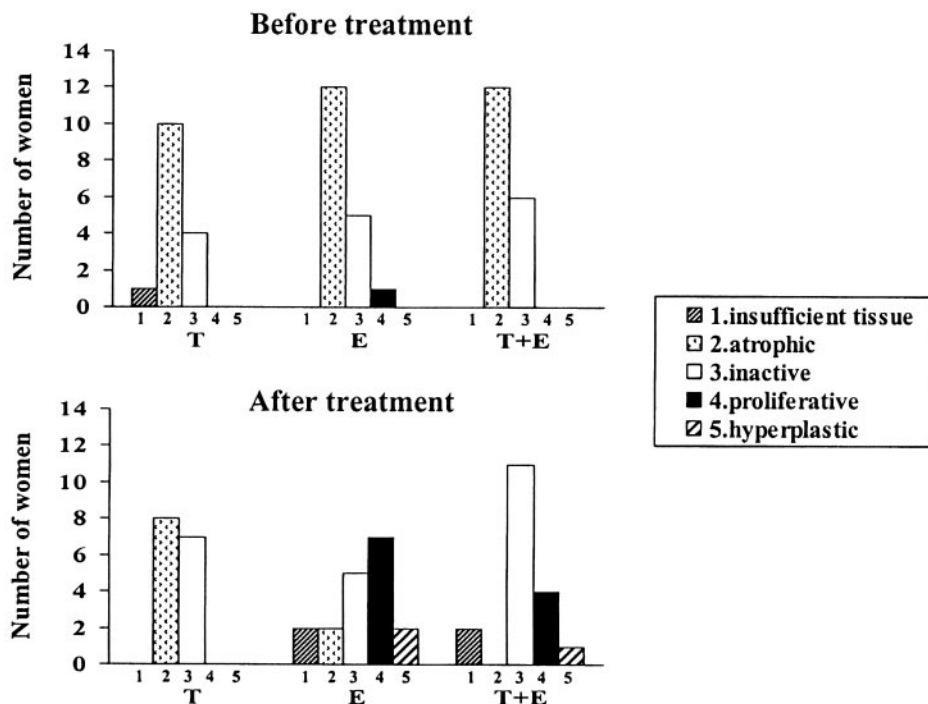
An amount of endometrial tissue sufficient for evaluation of the expression of Ki-67 by the same subject both before and

TABLE 1. Clinical characteristics, hormone levels, and endometrial thickness of our subjects at baseline and after treatment with testosterone (T group), estradiol (E group), and both (T+E group)

	T (n = 21)		E (n = 22)		T+E (n = 20)	
	Baseline	After treatment	Baseline	After treatment	Baseline	After treatment
Age (yr)	55 ± 4		55 ± 5		56 ± 4	
Age at menopause (yr)	50 ± 3		51 ± 4		50 ± 4	
Previous HT (n)	10		6		5	
BMI (kg/m ²)	24.1 ± 2.5	24.4 ± 2.8**	24.0 ± 2.3	24.3 ± 2.2*	24.9 ± 3.2	25.3 ± 3.1**
FSH (IU/liter)	78 (59–99)	80 (63–103)	66 (59–76)	34 (25–41)***	74 (58–88)	28 (18–45)***
E ₂ (pg/ml)	10 (8–12)	12 (9–17)	9 (8–15)	68 (38–100)***	12 (7–16)	88 (59–108)***
S-total T (ng/dl)	20 (17–29)	46 (26–141)***	23 (20–32)	23 (20–29)	26 (17–32)	40 (32–69)***
S-SHBG (mg/liter)	5.7 ± 1.4	5.0 ± 1.7	5.3 ± 1.8	10.8 ± 5.1***	4.8 ± 1.4	8.0 ± 2.4***
S-free T (pg/ml)	2.9 (2.3–4.3)	6.0 (4.2–20.7)***	3.7 (2.6–5.8)	2.1 (1.5–3.2)	3.7 (2.9–6.1)	4.2 (3.5–8.3)***
Endometrial thickness (mm)	1.7 (1.3–2.0)	1.4 (1.1–1.7)	1.7 (1.3–2.3)	5.8 (4.5–10)***	1.6 (1.2–2.2)	5.4 (2.7–8.4)***

The values presented are either means ± SD or median and quartile ranges (25th to 75th quartiles). Significant differences within the same group before and after treatment are denoted: *, $P < 0.05$; **, $P < 0.01$; ***, $P < 0.001$. Conversion factors to SI units: testosterone (T), 0.035 (nmol/liter); free testosterone, 3.467 (pmol/liter); estradiol (E₂) 3.7, (pmol/liter); SHBG, 10.9 (nmol/liter).

FIG. 2. The endometrial histopathology exhibited by postmenopausal women before and after treatment with TU (T group; n = 15), E₂V (E group; n = 18), or both (T+E group; n = 18). The classifications used were as follows: 1, insufficient tissue; 2, atrophic; 3, inactive; 4, proliferative; and 5, hyperplastic.



after treatment (paired samples) was obtained from five women in the E group and eight in the T+E group. The total number of samples large enough to be analyzed was, however, larger and included tissue from all three groups. Immunostaining of Ki-67 was observed in the nuclei of epithelial and stromal cells of the endometrium (Fig. 3). Such staining before and after treatment for one woman in each group is illustrated in Fig. 3.

As shown in Table 3, immediately before treatment, the percentage of cells in stroma and glands that expressed Ki-67 was similar for the three groups. After treatment, the percentage of Ki-67-positive cells in glands was clearly increased in both groups receiving estrogen but not in the case of the T group. In stroma, the treatment effect was in general less than in glands. However, the percentage of Ki-67-positive cells in stroma after treatment was highest in the E group and lowest in the T group. Moreover, the values in the E group were significantly higher than in the T+E group ($P < 0.05$). For the subjects in which a sufficient amount of tissue was obtained both before and after treatment allowing paired analysis, the percentage of Ki-67-positive cells was enhanced in both glands and stroma of the E and T+E groups ($P < 0.05$ for both). The values in the T+E group were numerically lower than in the E group. However, there was no statistical

difference between groups by this small sample size ($P = 0.14$ for stroma; $P = 0.35$ for glands).

Discussion

Our basic understanding of the effects of testosterone on the human endometrium is highly limited. To our knowledge, this is the first clinical comparison of the effects of testosterone and estrogen on endometrial proliferation in postmenopausal women. In this present open but randomized study, we found that, in contrast to estrogen, short-term treatment with testosterone does not stimulate this proliferation. Moreover, the degree of endometrial proliferation in the women receiving both testosterone and estrogen was less than those treated with estrogen alone.

TU is a testosterone preparation absorbed via the lymphatic intestinal system. Previous studies have shown that there are considerable intra-individual and interindividual variation of serum testosterone with this treatment (18). A 40-mg daily dose of TU was reported previously to give rise to testosterone levels exceeding the upper reference limit in about 50% of postmenopausal women (18). In the present study, we therefore treated postmenopausal women with 40 mg TU every second day. The treatment resulted in a 2-fold

TABLE 2. The relative proportions of atrophic and proliferative pattern at baseline and after treatment among the groups of subjects receiving testosterone (T group), estradiol (E group), or both (T+E group)

Pattern of endometrial histopathology	T group (n = 15)		E group (n = 18)		T+E group (n = 18)	
	Baseline	After treatment	Baseline	After treatment	Baseline	After treatment
Atrophic, n value (%)	15 (100)	15 (100)	17 (94)	9 (50)*	18 (100)	13 (72)
Proliferative, n value (%)	0 (0)	0 (0)	1 (6)	9 (50)*	0 (0)	5 (28)

The values presented are number of subjects (percentage). Significant differences within groups are denoted: *, $P < 0.05$.

increase of total testosterone levels with median levels within the normal range of premenopausal women.

It is well known that treatment of postmenopausal women with estrogen alone is associated with an increased rate of hyperplasia and risk of developing endometrial cancer (2, 19), with the rate of hyperplasia being related to the dose and duration of treatment. A prospective 1-yr study revealed that endometrial hyperplasia developed in 30% of the postmenopausal women receiving cyclic treatment with 0.625 mg conjugated equine estrogens and in 57% of those treated with 1.25 mg (20). This effect could, however, be attenuated by the additional administration of a progestin. With continuous combined HT, an atrophic endometrium is observed in a majority of women, whereas proliferative activity without atypical hyperplasia is present in approximately 2–3% (21).

In the present short-term investigation, a significant elevation in the rate of endometrial proliferation, including two women with simple hyperplasia, was found in the E group. In contrast, endometrial thickness and histopathology were not altered by treatment with testosterone alone. In the case of the T+E group, the rate of endometrial proliferation was not significantly enhanced, although there was an increase in the thickness of the endometrium. The tendency toward a higher rate of proliferation in the E group than in the T+E group indicates that testosterone may counteract the endometrial proliferation induced by estrogen.

Imhof *et al.* (22) have reported that treatment of postmenopausal women with isoflavones derived from red clover leads to elevated serum levels of testosterone and a reduction in endometrial thickness. Moreover, treatment of female-to-male transsexuals with high doses of androgens results in variable degrees of endometrial atrophy (23). These findings are in agreement with those presented here. However, in other studies, the rate of endometrial hyperplasia in post-

menopausal women treated with both testosterone and estrogen was at least comparable in extent with that caused by estrogen alone (10, 11).

The level of expression of Ki-67, a protein used as an indicator of proliferation, correlates well with the degree of mitotic activity in tissues (24). In the glandular epithelium of the endometrium, expression of Ki-67 is elevated during the proliferative phase but absent during the late secretory phase of the menstrual cycle (25). Guleria *et al.* (26) also found that this expression is decreased in both the glands and stroma of the endometrium of women using a copper intrauterine device, an observation that may explain the epidemiological evidence for a reduced risk for endometrial cancer among such women. In the present study, the expression of Ki-67 was up-regulated significantly in both glands and stroma of the endometrium of women in the E and T+E groups. However, the values were significantly lower in the stroma by combined treatment of estrogen and testosterone than by estrogen alone. These findings are consistent with the lower rate of endometrial proliferation associated with combined treatment compared with estrogen treatment alone indicated by histopathological examinations.

The regulation of endometrial proliferation in response to sex steroid hormones is complex and poorly understood. Estrogen, which exerts its functions via specific receptors (ER α and ER β), acts both at genomic and nongenomic levels (27). The human endometrium is incapable of aromatizing androgens to produce estradiol (28, 29). Cardenas *et al.* (30) have demonstrated that dihydrotestosterone attenuates estrogenic effects in the pig uterus by down-regulating ER α . Another study revealed that the antiprogestin mifepristone inhibits endometrial proliferation and up-regulates the androgen receptor in women (31). In addition, the antiandrogen flutamide blocks the suppressive effects of antiprogestins in the primate endometrium, which indicates that the androgen receptor may play a role in the antiproliferative effect of antiprogestins (32).

Androgens are used alone or in combination with estrogen to treat sexual dysfunction and loss of energy in postmenopausal women (4, 5). However, little is presently known about the possible side effects and safety of such treatment, and reports concerning the effects of testosterone on the endometrium are scarce. In this context, our findings do not give rise to any concerns about treating postmenopausal women with testosterone undecanoate for 3 months with a dose resulting in median serum levels of testosterone within the normal range for premenopausal women. However, longer-term studies with other testosterone preparations and other doses are warranted.

One limitation of the present investigation was the difficulty encountered in obtaining sufficient amounts of endometrial tissue to allow histopathological and immunohistochemical examination. This was the case for the T group in particular because of atrophy of the endometrium, a situation, however, that does provide additional support for our conclusion that testosterone does not stimulate endometrial proliferation. Consequently, we were unable to perform statistical analysis with regard to the expression of Ki-67 by women treated with testosterone alone. We can therefore not exclude that the effects of testosterone on the proliferation

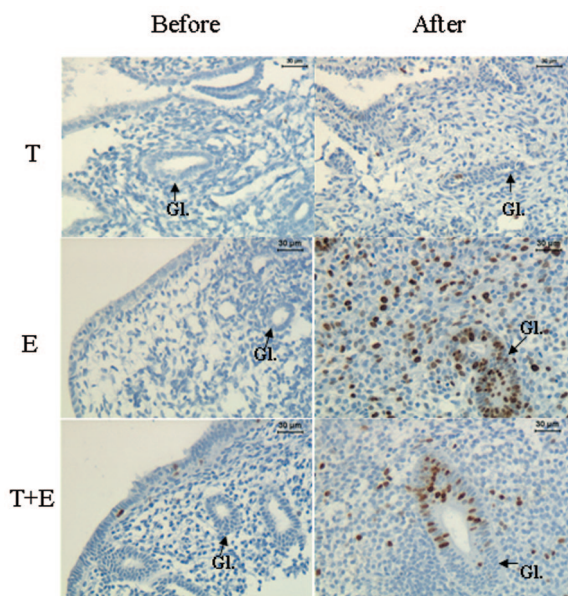


FIG. 3. Immunostaining of Ki-67-positive cells in the stroma and glands of endometrial tissue from one woman before (left) and after (right) treatment with TU (T group), E₂V (E group), or both (T+E group). Nuclei in proliferating cells are stained brown by the NCL-Ki-67-MM1 monoclonal antibody. Scale bars, 30 μ m. Gl, Gland.

TABLE 3. The percentage of Ki-67-positive cells in the endometrium of postmenopausal women before and after treatment with testosterone (T group), estradiol (E group), or both (T+E group)

	All samples					
	T group		E group		T+E group	
	Baseline (n = 3)	After treatment (n = 3)	Baseline (n = 6–7)	After treatment (n = 16–17)	Baseline (n = 9)	After treatment (n = 14)
% Glands	0.7 (0.7–20.3)	4.8 (1.7–8.0)	1.6 (0–2.2)	29.9 (19.5–38.5)	1.6 (0.8–3.4)	23.2 (14.3–31.2)
% Stroma	0.6 (0–0.7)	1.5 (0.4–4.8)	0.5 (0–2.4)	3.9 (3.0–19.9)	0.3 (0.2–0.5)	1.9 (1.0–4.6) [#]

	Paired samples			
	E group (n = 5)		T+E group (n = 8)	
	Baseline	After treatment	Baseline	After treatment
% Glands	1.9 (1.4–2.2)	36.2 (19.5–38.5)*	1.3 (0.4–3.3)	20.0 (12.9–29.6)*
% Stroma	0.8 (0.3–2.4)	3.1 (2.5–8.0)*	0.3 (0.1–0.5)	1.9 (0.7–4.0)*

The values are medians (25th to 75th quartile range). Significant difference between the E and T + E groups is denoted: #, $P < 0.05$. Significant differences within groups for paired samples are denoted: *, $P < 0.05$.

marker Ki-67 may have been underestimated. However, with respect to the histopathological evaluation, sufficient tissue was obtained from all but a few women in each group. The clinical characteristics of these few women did not differ in any apparent way from those of the other subjects.

In conclusion, our present findings indicate that short-term treatment of postmenopausal women with testosterone does not stimulate endometrial proliferation but may counteract such proliferation induced by estrogen. The long-term effects of testosterone treatment on endometrial proliferation and the risk for endometrial cancer remain to be elucidated.

Acknowledgments

This work was supported by the Swedish Research Council [Grants 20324 (to A.L.H.) and 20137 (to L.S.)] and the Karolinska Institutet.

Received October 4, 2006. Accepted February 28, 2007.

Address all correspondence and requests for reprints to: Hong Zang, M.D., Department of Woman and Child Health, Division of Obstetrics and Gynecology, Karolinska Institutet, SE-171 76 Stockholm, Sweden. E-mail: hong.zang@ki.se.

The authors have nothing to disclose.

References

- Smith DC, Prentice R, Thompson DJ, Herrmann WL 1975 Association of exogenous estrogen and endometrial carcinoma. *N Engl J Med* 293:1164–1167
- Feeley KM, Wells M 2001 Hormone replacement therapy and the endometrium. *J Clin Pathol* 54:435–440
- Mertens HJ, Heineman MJ, Koudstaal J, Theunissen P, Evers JL 1996 Androgen receptor content in human endometrium. *Eur J Obstet Gynecol Reprod Biol* 70:11–13
- Sherwin BB 1988 Affective changes with estrogen and androgen replacement therapy in surgically menopausal women. *J Affect Disord* 14:177–187
- Flöter A, Nathorst-Böös J, Carlström K, von Schoultz B 2002 Addition of testosterone to estrogen replacement therapy in oophorectomized women: effects on sexuality and well-being. *Climacteric* 5:357–365
- Davis SR, McCloud P, Strauss BJ, Burger H 1995 Testosterone enhances estradiol's effects on postmenopausal bone density and sexuality. *Maturitas* 21:227–236
- Watts NB, Notelovitz M, Timmons MC, Addison WA, Wiita B, Downey LJ 1995 Comparison of oral estrogen and estrogens plus androgen on bone mineral density, menopausal symptoms, and lipid-lipoprotein profiles in surgical menopause. *Obstet Gynecol* 85:529–537
- Rose GL, Dowsett M, Mudge JE, White JO, Jeffcoate SL 1988 The inhibitory effects of danazol, danazol metabolites, gestrinone, and testosterone on the growth of human endometrial cells in vitro. *Fertil Steril* 49:224–228
- Narukawa S, Kanzaki H, Inoue T, Imai K, Higuchi T, Hatayama H, Kariya M, Mori T 1994 Androgens induce prolactin production by human endometrial stromal cells in vitro. *J Clin Endocrinol Metab* 78:165–168
- Gelfand MM, Ferenczy A, Bergeron C 1989 Endometrial response to estrogen-androgen stimulation. *Prog Clin Biol Res* 320:29–40
- Hickok LR, Toomey C, Speroff L 1993 A comparison of esterified estrogens with and without methyltestosterone: effects on endometrial histology and serum lipoproteins in postmenopausal women. *Obstet Gynecol* 82:919–924
- Mutter GL, Ferenczy A 2002 Anatomy and histology of the uterine corpus. In: Kurman RJ, ed. *Blaustein's pathology of the female genital tract*. 5th ed. New York: Springer-Verlag; 383–419
- Ronnett BM, Kurman RJ 2002 Precursor lesions of endometrial carcinoma. In: Kurman RJ, ed. *Blaustein's pathology of the female genital tract*. 5th ed. New York: Springer-Verlag; 467–500
- Gerdes J, Li L, Schlueter C, Duchrow M, Wohlenberg C, Gerlach C, tahmer I, Kloth S, Brandt E, Flad HD 1991 Immunohistochemical and molecular biologic characterization of the cell proliferation-associated nuclear antigen that is defined by monoclonal antibody Ki-67. *Am J Pathol* 138:867–873
- Mokry J 1996 Versatility of immunohistochemical reactions: comprehensive survey of detection systems. *Acta Medica (Hradec Kralove)* 39:129–140
- Wang H, Masironi B, Eriksson H, Sahlin L 1999 A comparative study of estrogen receptors α and β in the rat uterus. *Biol Reprod* 61:955–964
- Zang H, Carlström K, Arner P, Lindén Hirschberg A 2006 Effects of treatment with testosterone alone or in combination with estrogen on insulin sensitivity in postmenopausal women. *Fertil Steril* 86:136–144
- Flöter A, Carlström K, von Schoultz B, Nathorst-Böös J 2000 administration of testosterone undecanoate in postmenopausal women: effects on androgens, estradiol, and gonadotrophins. *Menopause* 7:251–256

19. Wright TC, Holinka CF, Ferenczy A, Gatsonis CA, Mutter GL, Nicosia S, Richart R 2002 Estradiol-induced hyperplasia in endometrial biopsies from women on hormone replacement therapy. *Am J Surg Pathol* 26:1269–1275
20. Gelfand MM, Ferenczy A 1989 A prospective 1-year study of estrogen and progestin in postmenopausal women: effects on the endometrium. *Obstet Gynecol* 74:398–402
21. Horn LC, Dietel M, Eibenkel J 2005 Hormone replacement therapy (HRT) and endometrial morphology under consideration of the different molecular pathways in endometrial carcinogenesis. *Eur J Obstet Gynecol Reprod Biol* 122: 4–12
22. Imhof M, Gocan A, Reithmayr F, Lipovac M, Schimitzek C, Chedraui P, Huber J 2006 Effects of a red clover extract (MF11RCE) on endometrium and sex hormones in postmenopausal women. *Maturitas* 55:76–81
23. Miller N, Bedard YC, Cooter NB, Shaul DL 1986 Histological changes in the genital tract in transsexual women following androgen therapy. *Histopathology* 10:661–669
24. Gerdes J, Lemke H, Baisch H, Wacker HH, Schwab U, Stein H 1984 Cell cycle analysis of a cell proliferation-associated human nuclear antigen defined by the monoclonal antibody Ki-67. *J Immunol* 133:1710–1715
25. Mertens HJ, Heineman MJ, Evers JL 2002 The expression of apoptosis-related proteins Bcl-2 and Ki67 in endometrium of ovulatory menstrual cycles. *Gynecol Obstet Invest* 53:224–230
26. Guleria K, Agarwal N, Mishra K, Gulati R, Mehendiratta A 2004 Evaluation of endometrial steroid receptors and cell mitotic activity in women using copper intrauterine device: can Cu-T prevent endometrial cancer? *J Obstet Gynaecol Res* 30:181–187
27. Speroff L 2000 A clinical understanding of the estrogen receptor. *Ann NY Acad Sci* 900:26–39
28. Baxendale PM, Reed MJ, James VH 1981 Inability of human endometrium or myometrium to aromatize androstenedione. *J Steroid Biochem* 14:305–306
29. Bulun SE, Lin Z, Imir G, Amin S, Demura M, Yilmaz B, Martin R, Utsunomiya H, Thung S, Gurates B, Tamura M, Langoi D, Deb S 2005 Regulation of aromatase expression in estrogen-responsive breast and uterine disease: from bench to treatment. *Pharmacol Rev* 57:359–383
30. Cardenas H, Pope WF 2004 Attenuation of estrogenic effects by dihydrotestosterone in the pig uterus is associated with downregulation of the estrogen receptors. *Biol Reprod* 70:297–302
31. Narvekar N, Cameron S, Critchley HO, Lin S, Cheng L, Baird DT 2004 Low-dose mifepristone inhibits endometrial proliferation and up-regulates androgen receptor. *J Clin Endocrinol Metab* 89:2491–2497
32. Slayden OD, Brenner RM 2003 Flutamide counteracts the antiproliferative effects of antiprogesterins in the primate endometrium. *J Clin Endocrinol Metab* 88:946–949

JCEM is published monthly by The Endocrine Society (<http://www.endo-society.org>), the foremost professional society serving the endocrine community.